

SEPTAL PERFORATION PRESENTATION AND RECONSTRUCTION

RUSSELL W.H. KRIDEL, MD

In most facial plastic or otolaryngology practices, patients with septal perforations are most commonly seen both with and without symptoms after previous nasal or sinus surgery, nasal picking, or after cocaine use. Although these are the most common causes, a clear-cut etiology must be established from a long list of potential causes, some of which can be life-threatening. Septal perforation repair is technically challenging because the perforation represents a hole in three distinct tissue layers: the right and left septal mucoperichondrial flaps and the absent intervening cartilage. Both mucoperichondrial flaps, which are usually adherent to each other, must be distinctly separated and repaired individually, and the space in between should be filled with a connective tissue graft.

Although many procedures have been described to repair septal perforations, those techniques resulting in the highest success rate, best physiologic outcome, and best patient acceptance generally require using extensively mobilized, bilateral, intranasal mucosal advancement flaps and interposition and anchoring of a connective tissue-type graft. The success of repair is directly related to the size of the perforation, the presence or absence of scarring, metaplasia or inflammation, and the surgeon's experience. Because this repair is so difficult, prevention is always the best alternative.

Initial Examination and Patient Instruction

Symptoms

If patients are symptomatic with septal perforation, complaints are usually of crusting and bleeding along with

rhinorrhea, but rarely pain. If the perforation is small, patients may complain of nasal whistling, or alternatively, if the perforation is large, they may complain of nasal obstruction. The further anterior the perforation on the septum, the more common for the patient to be symptomatic because this area of the nose is likely to be drier due to air flow. Sometimes if the perforation is small and posterior, no symptoms are present and the perforation will be found serendipitously on physical examination. Large perforations generally cause more symptoms of nasal obstruction because they disrupt the normal separate lamellar flow.^{1,2}

The symptom of pain suggests the possibility of chondritis which can occur around the edges of the exposed cartilage at the circumference of the perforation. No assurances should ever be made that pain will resolve as this is subjective with each patient. Most perforations that are initially small enlarge due to continued inflammation, infection, drying of the residual nasal mucosa due to turbulent air flow, as a direct effect of continued exposure to a chemical irritant, or due to an underlying disease process. If the nose is allowed to stay dry internally, more crusting develops, patients attempt to pull out crusts and more bleeding ensues and the process worsens. Patients should be instructed to irrigate the nose several times a day with emollients to help improve the dryness and the crusting.

On initial examination, the septum should be palpated with a cotton-tipped applicator to determine if there is any residual cartilage between the mucosal flaps around the perforation site. In perforations after septoplasty, there is usually very little cartilage left around the perforation, making dissection of the adherent flaps much

more difficult (Figure 28-1). When the etiology is self-inflicted trauma or just minimal previous cocaine use, there may be large amounts of intervening septal cartilage and bone at the periphery of the perforation, which makes the repair easier. However, with extensive cocaine use and also in patients with a granulomatous process or vasculitis, the surrounding mucosa may be of poor quality, with crusting, squamous metaplasia with loss of the normal ciliated respiratory epithelium, and a decreased vascular supply due to scarring. In addition, the quality of the remaining septal cartilage may be compromised, thinned, and weak. All such cases must be evaluated individually, and not all can be repaired because they will not heal.

Patients often have no understanding of the complexity and difficulty of a septal perforation repair and need to be instructed that operative repair is not always successful and it is often necessary to repair normal physiology. It is helpful to show the patient an endoscopic view of their perforation on a monitor to explain what needs to be done (Figure 28-2).³ Sometimes less experienced physicians may tell patients that perforations are not repairable; this only delays the surgical treatment and allows the once-small perforation to enlarge to the point it is irreparable.

Etiology

Once iatrogenic or traumatic causes for the perforation are ruled out, other etiologies must be considered. A septal perforation may be the first sign of a potentially life-threatening generalized systemic process. Table 28-1 outlines the multiple

causes for septal perforations. More detailed discussion can be found in Kridel.⁴

Iatrogenic Causes

The largest contributing cause of a septal perforation in patients seen in my practice is iatrogenic, occurring after previous nasal surgery, especially septoplasty, and from cauterization and/or tight packing for epistaxis. During septoplasty, there may have been tears in both septal membranes in a contiguous area where the intervening septal cartilage or bone has been removed. If these are not repaired immediately at the time of surgery, the contraction of healing itself will enlarge the perforation. It is unwise to assume that a perforation will heal on its own. It is also imprudent to leave a large tear in the septal mucosa unsutured at the end of a septoplasty as a "ventilation window" to prevent hematoma, even when unilateral. Unilateral tears likely will heal if the opposite flap is intact, but suturing the edges of the tear together promotes faster healing and less thinning of the healed mucosa.

Nasal Sprays and Cocaine Usage

Some steroid nasal sprays can be very irritating to the septal mucosa when used on a long-term basis and can lead to perforation.⁵ It is the obligation of the physician who places patients on such sprays to examine the nasal mucosa for any untoward effect of the medication on a periodic basis. Patients in drier climates with low humidity and previous septoplasty patients may be more prone to damage.

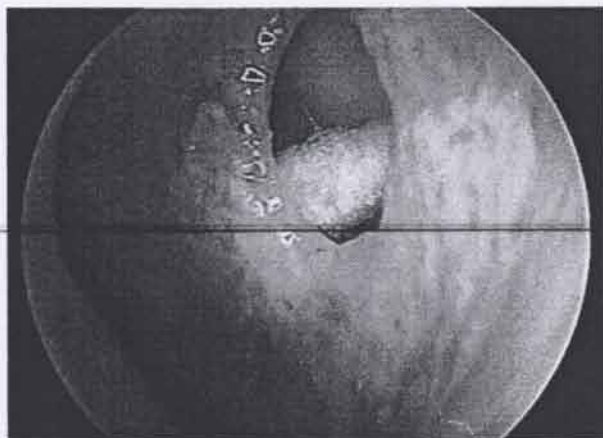


Figure 28-1. Endoscopic view of a septal perforation in a patient who had previous septoplasty with removal of almost all the septal cartilage and bone. A cotton-tip swab is used to palpate the paper thin adherent flaps and confirm the absence of septal cartilage. (©Russell W. H. Kridel, MD. Used with permission.)

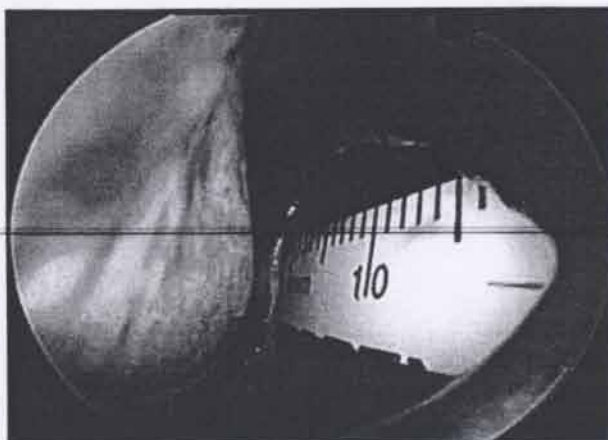


Figure 28-2. Endoscopic photo of paper ruler placed in the patient's nose to demonstrate to the patient the size, shape, and location of the perforation. (©Russell W. H. Kridel, MD. Used with permission.)

Table 28-1 Causes of Septal Perforation

Trauma	Self-inflicted	Iatrogenic	Drugs-legal and otherwise	Inflammatory Causes	Chemical Irritants	Neoplastic Causes	Infections
External	Nose picking	Nasal surgery	Vasoconstrictive nasal sprays	Vasculitides	Chromic, sulfuric, and hydrochloric acids	Adenocarcinoma	Tuberculosis
Fracture	Foreign bodies	Septoplasty	Steroid nasal sprays	Collagen vascular diseases	Chlorines and bromines	Squamous cell carcinoma	Syphilis
Septal hematoma		Sinus surgery	Cocaine	Sarcoidosis	Agricultural aerosolized dust	Metastatic carcinoma	Rhinoscleroma
Piercing injuries		Turbinate surgery	Smoking	Wegener's granulomatosis	Rice and grain elevator dust	Midline destructive granuloma	Lepromatous leprosy
		Rhinoplasty		Renal failure/renal disease	Chemical and industrial dusts		Rhinosporidiosis
		Septal cauterization			Lime		Multiple fungal species
		Septal packing			Cement		<i>Mucor</i>
		Septal splinting			Glass		Typhoid
		Cryosurgery			Salt		Diphtheria
		Trans-sphenoidal hypophysectomy			Dust		
		Postoperative suctioning			Heavy metal		
		Nasotracheal intubation			Cyanide, arsenicals		

Cocaine usage has increased dramatically as a major cause of septal perforations. The drug itself causes intense vasoconstriction compromising blood supply to the flaps. Since most street cocaine is adulterated with filler substances that can be quite irritating, such as Borax or talc, the insult to the septal membrane can be even worse. Even one-time usage of intranasal street cocaine has been known to cause a septal perforation.⁶ Chronic cocaine use can totally destroy the inside of the nose because often infection further complicates tissue inflammation, irritation, and lack of blood supply. The necrosis can progress not only to perforation but also to total nasal collapse, intranasal stenosis and scarring, and dorsal saddling. Because cocaine is a highly addictive substance, screening patients for continual use might be advisable. It is useless to attempt repair of septal perforation in a patient who is still using cocaine. Previous cocaine users should be instructed that even when cocaine use has been stopped, permanent damage may have occurred to the surrounding mucosa; this often compromises healing. However, each patient should be evaluated individually on a case-by-case basis as such surgery can be successful.

Systemic Diseases

Septal perforations can be the sequelae of serious systemic diseases, they may be neoplastic, inflammatory, or

infectious. When no obvious cause has been determined, the physician must rule out potential serious medical illnesses. Many systemic diseases can predispose to septal perforation including renal failure and renal disease, vasculitides, and collagen vascular disorders, such as lupus, rheumatoid arthritis, and polycondritis. Some of these conditions may recur after going into remission; thus it is wise to consult with the primary care physician before repair. These patients should be instructed that although repair is successful, the perforation can recur later with relapse of the illness. The author has noted this in several patients with renal and small vessel diseases.⁷ Wegener's granulomatosis, sarcoidosis, and other granulomatous diseases are less common causes, but a computed tomography (CT) scan of the nose and the paranasal sinuses helps to rule out these conditions.

Patient Evaluation and Diagnostic Tests

For those patients with no known etiology, negative head and neck examination, and negative CT scans, the workup should include laboratory evaluation for collagen vascular and renal disease, an FTA-ABS, VDRL, C-ANCA, and Epstein-Barr virus titers. Nasal cultures for fungi and bacteria are helpful in the presence of any inflammatory process and skin testing for allergy, tuberculosis, and fungal infections. As diagnostic tests are daily becoming more

advanced and specific, it can be helpful to consult with an immunologist/rheumatologist for the latest recommended tests.

Indications for Biopsy

If all tests prove negative and give no clear indication of cause, then a biopsy of the perforation may be necessary. The biopsy should be removed from the posterior edge of the perforation including enough tissue area away from the perforation to give the pathologist a definitive diagnosis, not just indication of chronic inflammation. Caution should be taken not to biopsy at the superior or inferior edge of the perforation which increases the height of the vertical perforation and impairs the surgeon's ability to close a perforation. Also biopsies should be avoided at the anterior portion of the perforation which is the preferred area for closing to decrease symptoms.

Surgical Prevention

If closure of contiguous tears is not undertaken, it is more likely that the perforation will enlarge postoperatively with the contraction of healing. Not only should contiguous membrane tears be repaired, but it is wise to insert intervening cartilage or a connective tissue graft as a barrier to perforation.⁸ Often obstructing cartilage that is removed during septoplasty is discarded or sent to pathology. This author, when performing a septoplasty, places crushed cartilage between the septal flaps in the area where the cartilage has been removed, regardless of whether tears in the septal membranes are present. Placing the cartilage back between the flaps (after being straightened or crushed), creates a barrier against perforation. Regardless of whether the cartilage survives, the resulting fibrosis between the septal flaps will strengthen the areas

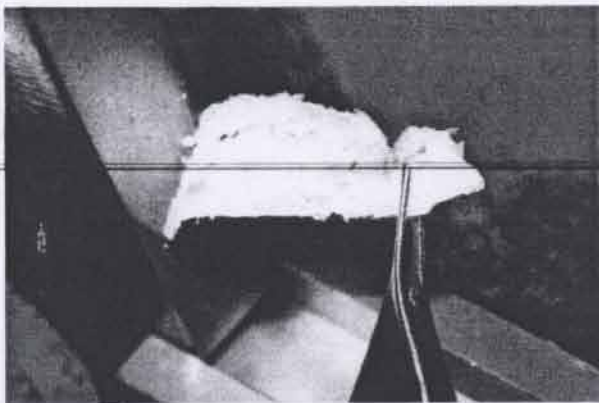


Figure 28-3. A piece of septal cartilage is crushed in a cartilage crusher and then placed back between the mucoperichondrial flaps to reskeletonize the septum and help prevent a perforation. (©Russell W. H. Kridel, MD. Used with permission.)

weakened by the removal of the cartilage. This may prevent a floppy septum syndrome (Figure 28-3).

The secret of preventing corresponding tears in both mucoperichondrial flaps during septoplasty is to broadly undermine and elevate the mucoperichondrium (at least on one side) away from the deviated cartilage or septal spur areas before attempting to remove the spur or the deviation. Even when there is a large spur, where penetrating the overlying membrane is quite common, the opposite mucoperichondrium usually can easily be elevated and maintained intact. If only one membrane is torn, the chance of a through-and-through perforation is markedly decreased. Before removal of a large, posterior, bony spur, the cartilage is separated from the bony septum and the mucoperichondrium elevated over the bony portion of the spur on the opposite side of the spur. Becker scissors are used to cut above and below the bony spur, and the tip of the nasal speculum is used to push the intervening spur closer to the midline as one teases the mucoperichondrium off the protruding portion of the spur before its removal. Often tears occur at the junction of the cartilaginous septum and the maxillary crest where there may be overlapping and/or deviation of the cartilage and bone. Tears may also be avoided by performing a floor elevation over the piriform bone and joining it to the septal flap, under direct visualization.

Bilateral, unrepaired, corresponding tears in septal membranes can still lead to septal perforation, even when intervening cartilage has been left. All such tears should be repaired. Blood supply to the cartilage comes from the overlying mucoperichondrium, and when it is disrupted bilaterally, the intervening cartilage can necrose and later perforate.

Medical, Nonsurgical Treatment

Asymptomatic patients with perforations rarely require any treatment. Such patients should be advised to keep the nose moist when in dry climates with the use of petrolatum-based ointment. For those patients with a considerable deal of crusting, frequent therapy with nasal irrigations and ointments/emollients is indicated. David Fairbanks recommends an antiseptic wash of one teaspoon of table salt dissolved in a quart of warm water as a nasal irrigant delivered via a Water Pik™ device with a nasal adapter.⁶ Corn syrup or glycerin can be added to the saline mixture as a moisturizing and coating substance which further reduces nasal crusting. A teaspoon of vinegar or 1 to 3 tablespoons of boric acid powder helps decrease *Staphylococcus aureus* and *Pseudomonas aeruginosa* growth. If there is a chronic infection, antibacterial ointments, such as bacitracin or Bactroban, may be initiated. A cool mist vaporizer by the bedside might also be helpful.

Patients often are bothered by such laborious treatment regimens and often prefer other solutions. A silicone grommet prosthesis does not fix the perforation but helps to restore better nasal air flow and does keep the edges of the perforation more moist. The commercially available buttons are not always of proper size to fit larger perforations, in which case a custom silicone button can be fabricated by the local prosthetist once given the proper dimensions.⁹ The standard or the custom-made septal buttons usually can be inserted in the office under local and/or topical anesthesia. When these buttons are in place, occasional nasal irrigations still may be necessary to keep the obturator clean; it may need to be removed for more adequate cleaning and for an integrity check yearly or more often. Such buttons are ideal for patients who are not good surgical candidates for medical reasons and should also be considered in those patients with a chronic or recurrent disease process and in any patient with continued cocaine usage.

Surgical Goals and Options

Restoring Normal Nasal Physiology

Surgery should not only repair the perforation but should also restore normal nasal function and physiology. The literature is replete with various closure techniques described, but only those using intranasal advancement flaps successfully achieve normal nasal physiology because nasal respiratory epithelium is used. Methods that use skin grafts or oral buccal mucosal grafts may be successful, but leave the patient with a dry nose that continues to crust as these grafts either shed or dry. The normal flow of air through the nose worsens the problem as it dries out these grafts.

Tension-Free Closure

The surgical method chosen should also achieve a tension-free closure so that the repair will not break down postoperatively as healing causes contraction. Because there is no elastic tissue in septal mucosa, methods that rely on septal advancement without adequate mobilization usually fail because the graft will not stretch. The open external rhinoplasty approach provides the necessary access and exposure for adequate mobilization and development of mucosal flaps which are advanced into place without attempting to stretch the flaps. By using sliding bipedicle or unipedicle flaps, usually from the floor of the nose and under the inferior turbinates, the surgeon can close the mucosal portion of the perforation with normal nasal respiratory mucosa. In addition, superior bipedicle flaps of mucosa can be elevated from under the upper lateral cartilages for extra membrane in larger perforations. Because these flaps have a blood supply, their

success rate is much higher than any composite graft which may not vascularize. In addition to closing the perforation in each mucoperichondrial flap, it is absolutely critical that a connective tissue interposition graft be placed between the flaps at the perforation repair site, to prevent recommunication and reperforation, and to act as a continuous surface on which the edges of the sewn perforation can migrate and mucosalize closed. This method of mucosalized flaps with an interposition graft has been described with over 90% success rate in perforations 2 to 3 cm, by several authors, including Fairbanks,⁶ Gollom,¹⁰ Kridel and colleagues,¹¹ and Goodman and Strelzow.¹²

Reducing Size of Perforation

As perforations increase in size, the chances of success decrease proportionately. Patients must be informed that even with small perforations, there is no guarantee of successful long-term closure. Romo and colleagues¹³ have described a method of tissue expansion to create larger advancement flaps for closure of these more difficult large perforations. Murrell and colleagues¹⁴ even described a repair using a forearm free flap which was anastomosed with the facial artery. Friedman and colleagues¹⁵ have described the inferior turbinate flap which is very helpful in caudal septal perforations, but the procedure is two-staged.

The anterior to posterior size of the perforation is not so important in closure because the tension of the closure is from the floor of the nose to the dorsum, which is perpendicular to this access. The height of the perforation is the most helpful determinate for the possibility and success of repair. Furthermore, it is not the overall size of the perforation but the proportion of remaining septal membrane that is more important. Perforations that extend all the way up to the nasal dorsum or extend back to the sphenoid are almost impossible to repair unless there is some small cuff of membrane to which the inferior advanced flap can be sutured. Previous septoplasty may make the dissection of the adherent mucosal flaps more difficult if a large amount of septal cartilage has been removed. Such dissection can lead to enlargement of the perforation during envelope separation. Adhesions between the remaining septal membranes and the lateral nasal wall or turbinates may need to be lysed in a separate, prior procedure placing silastic sheeting on the septum for several weeks to prevent reformation after septal repair.

Graft Selection

Many types of connective tissue grafts have been used to interpose between the repaired septal flaps, including mastoid periosteum, temporalis fascia, pericranium, septal bone or cartilage, fascia lata, acellular dermal allografts,¹⁶

and porcine small intestinal submucosa.¹⁷ Interposing such a connective tissue graft between the repaired septal flaps helps strengthen the repair and acts as a scaffold for the mucosa to creep on during the healing phase; this is especially important in cases where complete closure of the mucosal defect was not possible. Currently, the most commonly used grafts are the temporalis fascia and the dermal and the submucosal allografts (Figures 28-4 and 28-5). The temporalis fascia is harvested through a horizontal temporal incision; the incision is beveled to parallel the hair shafts to avoid injury to the hair follicles. Dissection is taken down to the deep temporal fascia. Injection of saline under the deep temporal fascia helps to elevate it off the temporalis muscle. A curved scissor is used to harvest the graft which should be considerably larger than the size of the septal perforation as the perforation itself may get enlarged during the process of flap dissection. After complete hemostasis is achieved, the temporal incision is closed in two layers, drained, and a mastoid-type pressure dressing is applied.

Surgical Approaches

The endonasal approach to perforation repair has been popularized by David Fairbanks.⁶ This method is highly successful but extremely difficult, especially in large perforations or in patients with small nostril apertures. When more exposure is needed, Fairbanks does a lateral alotomy, which has the potential for a visible external incision. The external rhinoplasty approach is quite advantageous in that it provides access to not only the anterior but also the superior and posterior aspects of the perforation. This provides increased surgical exposure and visualization and avoids distortion that normal intranasal retraction can cause. Furthermore, since no transfixion incision is made,

the anterior septal blood and lymphatic supply is preserved which may improve nasal advancement flap viability. With the external technique, one approaches the caudal end of the septum by totally separating the medial crura away from themselves and from the septum. This process interrupts the normal fibrous connections between the medial crura, the septum, and the overlying skin, which normally help to support and preserve tip projection. The careful surgeon must reconstitute tip support mechanisms after the perforation is repaired by not only suturing the medial crura back together with interrupted sutures but also at times by placing a columellar strut.

Surgical Technique—External Rhinoplasty Approach

The patient is placed in the supine position. After an adequate level of general oral endotracheal anesthesia is obtained, an oral pharyngeal throat pack is placed to prevent any blood from trickling down into the esophagus and stomach thus reducing the chances of any postoperative nausea. This is a long procedure and more difficult to perform under intravenous (IV) sedation. The nose and septum are then infiltrated with the combination of 1% xylocaine with 1:100,000 units of epinephrine. Time is allowed to elapse for the vasoconstrictive and anesthetic effect of the infiltrated solution while the patient is prepped and draped in the usual sterile fashion. Careful intranasal examination is done, and any intranasal synechiae or hypertrophied turbinates are dealt with at this stage.

A classical external rhinoplasty approach is performed where bilateral alar marginal incisions are started laterally along the caudal edge of the lateral crus; dissection is continued medially down the length of the columella where they are connected via an inverted V-shaped

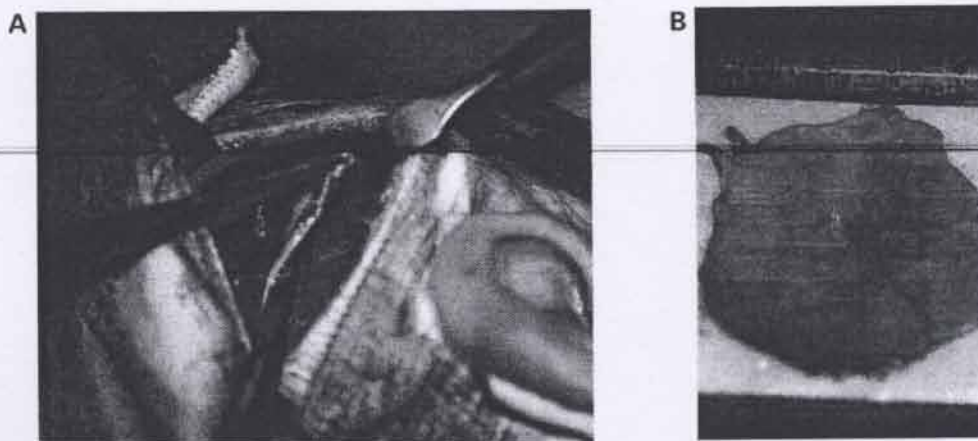


Figure 28-4. A, Harvesting the temporalis fascia. B, 4 × 4 cm piece of temporalis fascia spread out to dry prior to insertion between the mucoperichondrial flaps. (©Russell W. H. Kridel, MD. Used with permission.)

transcolumellar incision. The columellar skin is elevated off the medial crura and skin dissection continues upwards making sure to stay in the supraperichondrial avascular plane until reaching the nasal bones where the periosteum is elevated using a Joseph-type periosteal elevator. Dissection is performed between the medial crura to gain access to the caudal septal cartilage followed by bilateral caudal septal membrane elevation in a strict submucoperichondrial plane (Figure 28-6). The upper lateral cartilages are then sharply separated from the septum extramucosally (Figure 28-7), which provides excellent exposure as one approaches the perforation itself. Septal flap elevation is continued upwards until reaching the cartilaginous edge of the perforation where an increased resistance is met during the dissection due to the adherence of the septal flaps to each other with no intervening cartilage.

The mucosal perforation is now opened into, using a broad exposure technique and careful dissection to avoid any enlargement of the existing perforation. Dissection must proceed posteriorly for at least a centimeter back behind the perforation and any residual bony cartilaginous deviations can be corrected at this time. The dissection is then taken downwards to elevate the mucosa off the maxillary crest, nasal floor, and laterally until reaching the root of the inferior turbinate. Any bleeding encountered from the penetrating vessels at the maxillary crest should be cauterized using an insulated-tip suction cautery. After completing the nasal floor flap elevation, a posterior-to-anterior incision is made using a #15 blade inferior to the root of the inferior turbinate thus creating a bipediced mucosal flap which is attached both anteriorly and posteriorly to preserve its vascular supply (Figure 28-8). To allow this

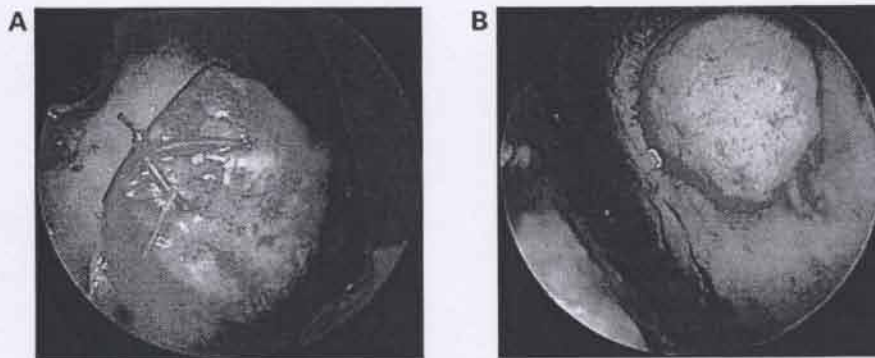


Figure 28-5. Insertion of AlloDerm between the mucoperichondrial flaps as an interposition acellular dermal graft. *A*, Endoscopic view between the mucoperichondrial flaps. The AlloDerm graft is sewn to the left side of the residual septum. *B*, Endoscopic view of the right nasal passage after the AlloDerm graft has been sutured to the septal cartilage and covers the entire septal perforation. (©Russell W. H. Kridel, MD. Used with permission.)

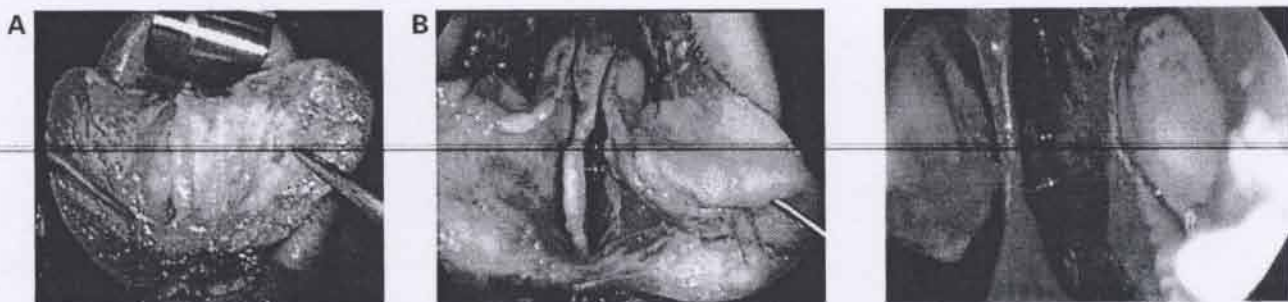

Figure 28-6. *A*, Intraoperative photograph showing the dissection and spreading apart of the medial crura to gain access to the caudal part of the septal cartilage. *B*, After bilateral mucoperichondrial flaps have been developed, the upper lateral cartilages are sharply cut away from the septum to provide improved access to the perforation. The mucoperichondrium is left intact and attached to the undersurface of the upper lateral cartilages. (©Russell W. H. Kridel, MD. Used with permission.)

Figure 28-7. Each mucoperichondrial flap is distinctly separated so each can be individually repaired. (©Russell W. H. Kridel, MD. Used with permission.)

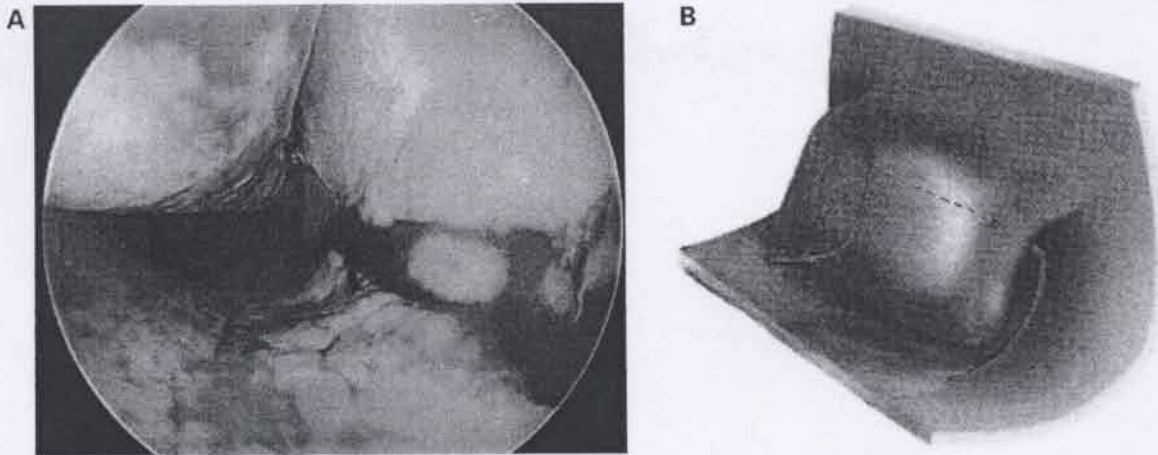


Figure 28-8. Endoscopic view and schematic of posterior-to-anterior incision made near the root of the inferior turbinate. Limited back-cuts may be performed anteriorly or posteriorly to facilitate advancement of the flap. The mucosal floor flap can then be advanced toward the septum to close the perforation. (©Russell W. H. Kridel, MD. Used with permission.)

lateral flap to be mobilized medially, anterior and posterior back-cuts are made from lateral to medial at each end of the flap; one then checks the flap for mobility to see how readily it can be brought medially and upward onto the nasal septum to see if the mucosal redundancy provided by the created flaps is adequate for closure. In larger perforations, the inferior advancement floor flaps alone cannot provide enough mucosa for closure, and a superiorly based flap may also be necessary. The superior roof flap which now bridges between the superior edge of the perforation and the undersurface of the upper lateral cartilage can be dropped downwards, by elevating it off the undersurface of the upper lateral cartilage to help in closing the mucosal perforation on each side. However, in exceptionally large perforations, a posterior to anterior cut could be made in the mucosa under the upper lateral cartilage, thus transforming the roof flap into a more released bipediced flap allowing more downwards advancement. This can only be performed on one side for fear that the dorsal cartilaginous septum would be exposed bilaterally. Loss of cartilaginous viability in the cartilaginous dorsal area may result in dorsal saddling or a high perforation.

Once enough mucosal laxity has been provided by these advancement flaps, the perforation in each mucoperichondrial flap is closed, under as little tension as possible, using interrupted sutures of either 4-0 or 5-0 chromic or plain gut sutures (Figure 28-9A and B). Any granulation tissue or scarring that is present at the periphery of the perforation should be removed before suturing to provide fresh edges that would be more likely to heal. At this point, the temporalis fascia graft, submucosal graft, or acellular dermal graft is used. This interposition graft is then placed between the

mucoperichondrial flaps and brought back posteriorly at least 1 cm beyond the closed perforation. The graft should then be stabilized to prevent postoperative movement by using a few individual sutures to sew it directly to the septal cartilage remnant. After fixation, the graft should be inspected to be certain that the center of the closed perforation is well covered by the graft.

The upper lateral cartilages must then be re-sutured to the septum. If the perforation was large and required superior advancement flaps, it may be difficult to reattach the upper lateral cartilages to the septum at their original height and at the same time avoid tension on the newly closed perforation site. The surgeon may be forced to re-secure the upper lateral cartilages to the septum at a lower level, with the potential cosmetic outcome being a pinched appearance to the nasal dorsum. The pinched appearance results from the upper laterals being lower than the central septal dorsum. Recognition of this potential problem would necessitate cartilaginous onlay grafts over the reset upper lateral cartilages to provide better dorsal symmetry. If a reduction rhinoplasty was carried out at the same time, this problem would be less of an issue. The internal nasal valve must also be evaluated at this time of re-suturing of the upper laterals and spreader grafts may also be necessary.

The intranasal septal flaps must then be matted together reapproximating both flaps and sandwiching the interposition graft. Mattressing the septum aids in the healing of the perforation and speeds the revascularization of the graft. It furthermore helps to prevent the occurrence of a postoperative hematoma. The mattress stitch is usually a 4-0 chromic suture and a continuous suture technique is used (Figure 28-10). The needle must

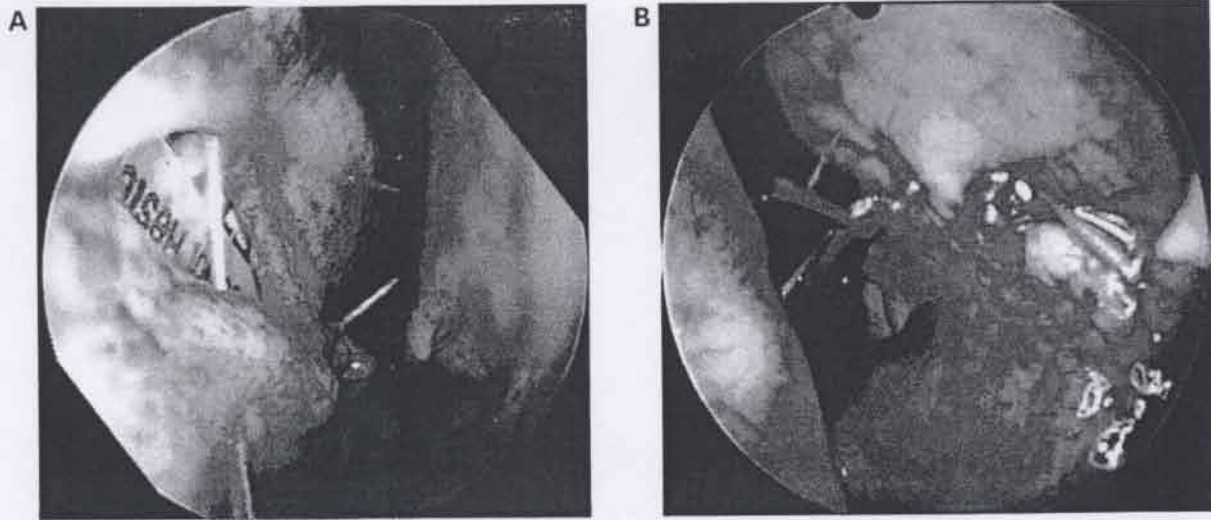


Figure 28-9. *A*, Endoscopic view of the left nasal passage showing the perforation during closure. A suture foil is used to protect the contralateral mucoperichondrial flap. Chromic or plain gut suture is used to approximate the superior and inferior edges of the perforation. *B*, Endoscopic view of the right nasal passage of the same patient after closure is completed. (©Russell W. H. Kridel, MD. Used with permission.)

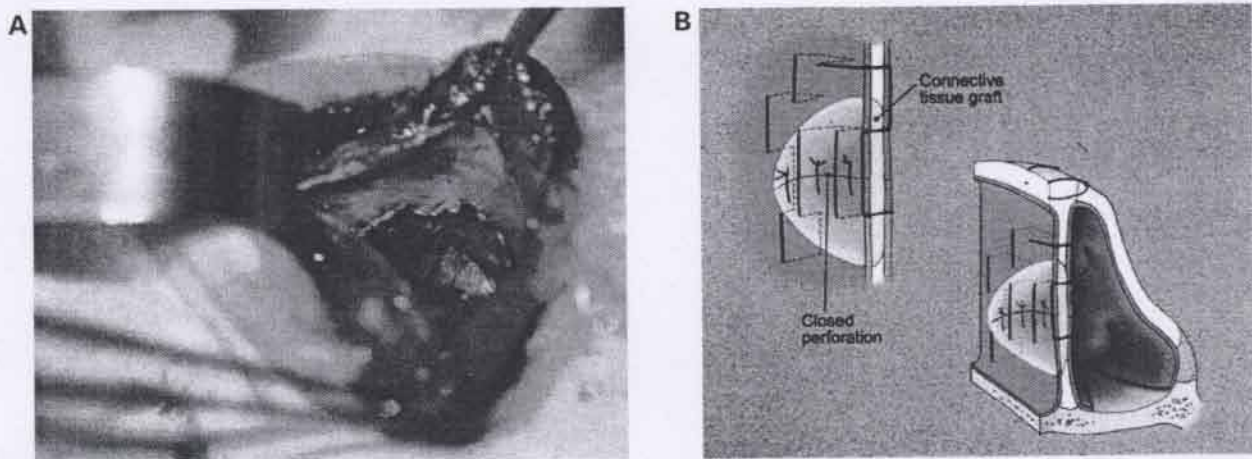


Figure 28-10. *A*, In this case, the temporalis fascia is used as the interposition graft and is shown here covering the perforation and sutured to the surrounding septal cartilage to prevent migration. (©Russell W. H. Kridel, MD. Used with permission.) *B*, The interposition graft is centered under the closed perforation using mattress sutures through both mucosal flaps and the graft. This prevents migration of the graft, holds the graft in apposition to the flaps to aid in healing, and prevents postoperative bleeding or hematoma formation.

be extremely sharp so that it passes freely through not only the flaps but also the graft and causes little displacement of the interposition graft. Mattress sutures must be used above and below the repaired perforation so that the sutures are placed in a perpendicular plane to that of the perforation repair. This suture technique strengthens and reinforces closure.

As noted previously, resupport of the nasal tip support mechanisms is crucial.⁴ The medial crura must be resutured together with or without a columellar strut. The nose should also be evaluated at this time to see if

there has been any unwanted rotation of the tip, due to tension of the closure, and due to continuity of the septal flaps with the mucosa of the medial crura. If unwanted rotation and shortening of the nose has occurred, the surgeon may use a caudal septal replacement graft to lengthen the nose or place a large cartilaginous batten in front of the medial crura to camouflage such rotation. A tip graft can also be added that does not extend above the dorsum, and so acts to provide extra length to the tip without increased rotation or projection. The dome cartilages must then be sewn

together with permanent sutures reconstructing the dome complex and preventing postoperative bossae. At completion of this resupport, the nasal skin is redraped to its normal anatomical position and the external rhinoplasty incisions closed. The transcolumellar incision is closed using a deep 6-0 PDS suture to take the tension off the skin edges, which are then approximated using a combination of interrupted 6-0 Prolene sutures and 6-0 fast-absorbing plain gut in a running locking fashion. The marginal incision is closed on each side using a 5-0 plain suture.

To protect the repaired septal flaps during their healing phase, a 0.020 inch thick polymeric silicone sheeting (Silastic) is placed on both sides of the septal flaps, covering almost all of the septum on each side and is secured into place by approximately three 5-0 nonabsorbable sutures (Figure 28-11). These sutures should not be overly tight, so as not to constrict the blood supply to the septum. Because these soft polymeric silicone sheets are transparent, the repair site can be visualized postoperatively with monitoring of the progress of the healing mucosa. Monitoring of the protected repaired site is especially helpful if the surgeon is unable to close the perforation fully. The sheeting protects the graft site from airflow drying and keeps the area moist to accelerate the healing process. The use of hard, heavier internal splints with or without airway tubes is not recommended as these are difficult to see through, are unwieldy, and hurt the patients when they are removed. The nose is then very lightly packed with Gelfoam strips underneath the inferior turbinates, followed by a small Telfa pack impregnated with antibiotic cream. If too much packing is placed, vascular compromise of the repair site could ensue as nasal swelling develops.

The Gelfoam is additionally helpful because it absorbs any bleeding as the result of the development of the bi-pediced flaps. The nose is then externally taped and splinted, whether or not any dorsal modifications or osteotomies have been done or grafts have been used. Elevation of the open rhinoplasty flap creates a potential space for blood accumulation and fibrosis postoperatively, and a standard external splint must be placed for prevention with the end of the splint being in the supratip where gentle pressure is applied by the splint. A drip pad is placed, and the patient is then extubated by anesthesia after the throat pack has been removed.

Postoperative Care

All patients should be instructed to expect some bloody discharge postoperatively, due to the raw areas underneath the inferior turbinates. This nasal discharge often lessens after the first 24 hours. On the first postoperative day, the Telfa packs are removed and the Gelfoam is usually left in place. No attempt should be made to remove all of the Gelfoam on the first operative day. The patient is instructed to use saline nose drops 3 to 4 times per day. This helps to keep the Gelfoam moist and allows easier suctioning over the next 7 to 10 days. Using cotton-tip applicators, the patient is encouraged to place antibacterial ointment on the incisions and within the nose to prevent postoperative crusting. The external nasal splint is usually removed at about 5 to 7 days, and then the nose is usually retaped for another 5 days. The nonabsorbable columellar sutures are removed at about the fifth day.

Careful examination of the site of the previous perforation is carried out through the clear Silastic sheeting at

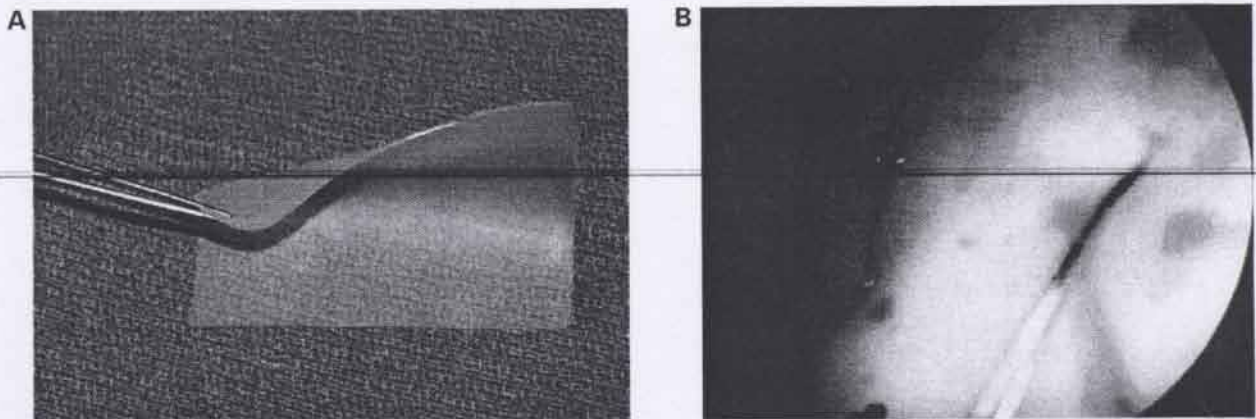


Figure 28-11. A, Clear 0.02 inch thick silicone soft sheeting is shaped to cover the perforation repair on each side of the septum. B, Silicone sheeting sutured in place with three through-and-through mattress sutures of 5-0 Prolene. Caution must be taken not to constrict the flaps and compromise the blood supply. These transparent sheets allow easy monitoring of healing of septal perforation repair. (©Russell W. H. Kridel, MD. Used with permission.)

each visit. In most cases, sheeting is left in place for 2 to 3 weeks, but that time can be extended if the perforation does not appear to be fully healed. If after removing the Silastic sheeting, there is still a small unhealed area, the patient is instructed to keep this area moist, using antibacterial ointment 3 to 4 times per day in addition to using a saline mist. Never do we pick on any crusts on the site of the healing perforation, as such sites usually heal with time and ointment.

The patient is instructed not to use any vasoconstrictive sprays, to refrain from smoking, and to avoid noxious fumes during the postoperative phase. Blowing the nose is also to be avoided for the first month postoperatively. If the patient had a temporalis fascia graft harvested, the drain is removed on the first day, the pressure dressing is maintained for 2 or 3 more days, and the sutures are removed in about 7 to 10 days.

Outcomes

The successful outcome of this operation is dependent upon many factors including the cause of the perforation, size and location of the perforation, the experience and surgical skill of the surgeon, the medical condition of the patient, and postoperative cooperation and compliance. If there is not success in totally closing the perforation, it is usually made smaller by this surgery. If complete closure is not likely, all perforations should be closed from an anterior to posterior direction, moving the perforation more posterior and thus decreasing patient symptoms. A repeat surgery can be attempted in about 6 to 12 months, if necessary, depending on individual patient factors.

After the perforation is completely healed, the patient can experience the same satisfaction as the physician in the successful closure. Photographic documentation once again can assist the patient in understanding this difficult and complex problem and to see the successful outcome. It is remarkable to see how well the septum may heal with no, or almost no, evidence of the previous perforation present, other than a sometimes visible scar.¹⁷

References

1. Belmont JR. An approach to large nasoseptal perforations and attendant deformity. *Arch Otolaryngol Head Neck Surg* 1985;450-5.
2. Kuriloff DB. Nasal septal perforations and nasal obstructions. *Otolaryngol Clin North Am* 1989;22:333-50.
3. Kridel RWH. Combined septal perforation repair with revision rhinoplasty. *Facial Plast Surg Clin North Am* 1995;3:459-72.
4. Kridel RWH. Septal perforation repair. *Otolaryngol Clin North Am* 1999;32:695-724.

5. Schoelzel EP, Menzel ML. Nasal sprays and perforation of the nasal septum. *JAMA* 1985;253:2046.
6. Fairbanks DN. Nasal septal perforation repair: 25-year experience with the flap and graft technique. *Am J Cosmet Surg* 1994;11:189-94.
7. Adler D, Ritz E. Perforation of the nasal septum in patients with renal failure. *Laryngoscope* 1980;90:317-21.
8. Trenite GJN, Verwoerd CDA, Verhoef V. Reimplantation of autologous septal cartilage in the growing nasal septum. *Rhinology* 1987;25:225-36.
9. Price DL, Sherris DA, Kern EB. Computed tomography for constructing custom nasal septal buttons. *Arch Otolaryngol Head Neck Surg* 1980;106:509-13.
10. Gollom J. Perforation of the nasal septum, the reverse flap technique. *Arch Otolaryngol Head Neck Surg* 1968;888:518-522.
11. Kridel RWH, Appling D, Wright W. Closure of septal perforations: a simplified method via the external septorhinoplasty approach. In: Ward P, Berman W, editors. *Plastic and Reconstructive Surgery of the Head and Neck: Proceedings of the Fourth International Symposium*; vol. I, 1983; Los Angeles. The C.V. Mosby Co; 1984. p. 183-8.
12. Goodman WS, Strelzow VV. The surgical closure of nasoseptal perforations. *Laryngoscope* 1982;92:121-4.
13. Romo T III, Jablonski RD, Shapiro AJ, McCormick SA. Long term nasal mucosal tissue expansion using repair of large nasoseptal perforations. *Arch Otolaryngol Head Neck Surg* 1995;121:327-31.
14. Murrell GL, Karakla DW, Messa A. Free flap repair of septal perforation. *Plast Reconstr Surg* 1998;102:818-21.
15. Friedman M, Ibrahim H, Ramakrishnan V. Inferior turbinate flap for repair of nasal septal perforation. *Laryngoscope* 2003;113:1425-1428.
16. Kridel RWH, Foda H, Lunde K. Septal perforation repair with a cellular human dermal allograft. *Arch Otolaryngol Head Neck Surg* 1998;124:73-8.
17. Kridel RWH, Foda H. Nasal septal perforation: prevention, management, and repair. In: Ira D, Papell MD, editors. *Facial plastic and reconstructive surgery*. 2nd ed. New York: Thieme; 2002. Chap. 41, p. 473-81. (This publication adapted from this article.)

Further Readings

- Ambro BT, Zimmerman J, Rosenthal M, Pribitkin EA. Nasal septal perforation repair with porcine small intestinal submucosa. *Arch Facial Plast Surg* 2003;5:528-9.
- Fairbanks DN. Closure of nasal septal perforations. *Arch Otolaryngol Head Neck Surg* 1980;106:509-13.
- Foda HMT. The one-stage rhinoplasty septal perforation repair. *J Laryngol Otol* 1999;113:728-33.
- Gray I. Deviated nasal septum: its influence on the physiology and disease of the nose and ear. *J Laryngol* 1967;81:953-86.

- Karlan MS, Ossoff R, Sisson GA. A compendium of intranasal flaps. *Laryngoscope* 1982;92:774-82.
- Kridel RWH. The open approach of repair of septal perforations. In: Daniel RK, editor. *Aesthetic plastic surgery: rhinoplasty*. Boston (MA): Little Brown and Company; 1993. p. 555-66.
- Kridel RWH, Appling D, Wright W. Septal perforation closure utilizing the external septorhinoplasty approach. *Arch Otolaryngol Head Neck Surg* 1986;112:168-72.
- Kridel RWH, Konior R. Use of irradiated cartilage graft in the nose. *Arch Otolaryngol Head Neck Surg* 1993;119:24-31.
- Kridel RWH, Lunde K. Nasal septal reconstruction, review and update. *Facial Plast Surg Clin North Am* 1999; 7:105-13.
- Romo TR, Foster CA, Korovin GS. Repair of nasal septal perforation utilizing the midface degloving technique. *Arch Otolaryngol Head Neck Surg* 1988;114:739-42.
- Romo T III, Sclafani AP, Falk AN, Toffel PH. A graduated approach to the repair of nasal septal perforations. *Plast Reconstr Surg* 1999;103:66-75.